

The Effect of Smoking on Oral Labial Mucosa: A Controlled Dermoscopic Study

Erhan Ayhan, Isa An¹, Murat Öztürk², Esref Araç³

Departments of Dermatology and ³Internal Medicine, Gazi Yaşargil Training and Research Hospital, University of Health Sciences, Diyarbakir, ¹Department of Dermatology, Şanlıurfa Training and Research Hospital, Şanlıurfa, ²Department of Dermatology, Van Training and Research Hospital, Van, Turkey

Abstract

Background/Aim: Although the effects of smoking on large blood vessels are known, research on the effects of smoking on microcirculation continues. In this study, we investigated whether the dermoscopic features of the labial mucosa of smokers differed from the healthy control group. **Materials and Methods:** In this study, 164 patients (82 smokers and 82 nonsmokers) aged between 20 and 75 years who were admitted to the dermatology department were included. Dermoscopically obtained data were analyzed. **Results:** Hemorrhagic dot (48.8% vs. 26.8%, $P: 0.004$), matchstick hairpin vessels (37.8% vs. 15.9%, $P: 0.002$), microaneurysm (35.4% vs. 18.3%, $P: 0.014$), targetoid brown round areas (37.8% vs. 19.5%, $P: 0.010$), white dot (22% vs. 9.8%, $P: 0.033$), and hyperkeratosis (37.8% vs. 18.3%, $P: 0.005$) were found to be significant in terms of dermoscopic features. **Conclusion:** In this study, we think that structures such as hemorrhagic dot, matchstick hairpin vessels, microaneurysm, which are found to be high in smokers, may be caused by microcirculation disorders.

Keywords: Dermoscopy, labial mucosa, smoking

INTRODUCTION

Smoking is an important modifiable risk factor for cardiovascular disease, and its effects on large-vessel atherosclerosis and thrombosis are well known.^[1] Due to the difficulties in imaging the microcirculation, the effect of smoking on the microvascular structure is less pronounced.^[2] At present, efforts are being made to clarify the effects of tobacco smoke on microcirculation. The presence of endothelial dysfunction is considered to be an early marker of vascular injury that is prone to the development of atherosclerotic lesions.^[3] However, smoking also releases free radicals and pro-oxidant factors that may result in inflammation and oxidative damage to the vascular endothelium and impair coronary circulation functions.^[4]

The information about the vascular structures of the oral mucosa has been presented by studies on capillaroscopy. Labial mucosal visibility is probably the best in the oral region.^[5] The chronic smoking habit creates significant morphological changes in the microcirculation of the human

labial mucosa and these changes can be easily recorded by videocapillaroscopy.^[6] Capillaroscopic examination revealed that the diameter of the capillary loops in the labial mucosa decreased and their number increased and the presence of more pronounced tortuous capillary loops.^[6] However, there are no dermoscopic studies showing the effect of smoking, the changes on vascular and nonvascular structures in the labial mucosa. In this study, the dermoscopic examination of the oral labial mucosa of smokers and nonsmokers was performed comparatively.

MATERIALS AND METHODS

The study included 82 smokers (at least 2 years) and 82 nonsmokers, who presented to the dermatology department and aged 20–75 years. Patients with diseases that could affect microcirculation such as diabetes, hypertension,

Address for correspondence: Dr. Erhan Ayhan, Department of Dermatology, Gazi Yaşargil Training and Research Hospital, University of Health Sciences, Diyarbakir, Turkey. E-mail: nanodunya@hotmail.com

Submission: 30-11-2019

Revision: 30-11-2019

Acceptance: 21-12-2019

Web Publication: 25-02-2020

Access this article online

Quick Response Code:



Website:
www.tjdonline.org

DOI:
10.4103/TJD.TJD_41_19

This is an open access journal, and articles are distributed under the terms of the Creative Commons Attribution-NonCommercial-ShareAlike 4.0 License, which allows others to remix, tweak, and build upon the work non-commercially, as long as appropriate credit is given and the new creations are licensed under the identical terms.

For reprints contact: reprints@medknow.com

How to cite this article: Ayhan E, An I, Öztürk M, Araç E. The effect of smoking on oral labial mucosa: A controlled dermoscopic study. Turk J Dermatol 2020;14:14-7.

hyperlipidemia, and heart disease and patients receiving medical treatment were not included in the study.

This study includes three stages including dermatological and dermoscopic examination of the lesions, macroscopic and dermoscopic (Dermatoscope Delta 20; Heine, Herrsching, Germany; Handyscope Fotofinder Systems) photographing, and evaluation of the findings. Macroscopic (at least 2) and dermoscopic (at least 15) pictures of all lesions in the study were taken and the data were recorded. Vascular structures and nonvascular structures were defined as dermoscopically. The pressure on the lesion was relieved to prevent collapse of the vascular structures.

All patient data were uploaded to SPSS 21.0 statistic application software (SPSS Inc., Chicago, IL, USA). The data were analyzed with the Student's *t*-test for independent samples with regard to parametric data and with the Mann-Whitney U-test with regard to nonparametric data. $P < 0.05$ was considered statistically significant.

RESULTS

The study included 82 smokers (64 men and 18 women; mean \pm standard deviation [SD] age 38.15 ± 13.54 ; patients range 20–73) and 82 nonsmokers (64 men and 18 women; mean \pm SD age 36.62 ± 16.99 ; patients range 20–75). There was no significant difference between the groups in terms of age ($P > 0.05$).

Hemorrhagic dot (48.8% vs. 26.8%, $P: 0.004$), matchstick hairpin vessels (37.8% vs. 15.9%, $P: 0.002$), microaneurysm (35.4% vs. 18.3%, $P: 0.014$), targetoid brown round areas (37.8% vs. 19.5%, $P: 0.010$), white dot (22% vs. 9.8%, $P: 0.033$), and hyperkeratosis (37.8% vs. 18.3%, $P: 0.005$) were found to be significant in terms of dermoscopic features.

There was no significant difference between the two groups in terms of deep vascular network (92.7% vs. 96.3%, $P: 0.304$), superficial vascular network (90.2% vs. 96.3%, $P: 0.191$), mixed retinal arrangement (82.9% vs. 74.4%, $P: 0.182$), grouped hairpin vessels (70.7% vs. 62.2%, $P: 0.247$), dot vessels (54.9% vs. 47.6%, $P: 0.349$), chain hairpin vessels (24.4% vs. 17.1%, $P: 0.248$), clear reticular arrangement (17.1% vs. 25.6%, $P: 0.086$), glomerular vessels (2.4% vs. 6.1%, $P: 0.246$), yellow background areas (95.1% vs. 91.5%, $P: 0.349$), yellowish-white streaks (30.5% vs. 26.8%, $P: 0.604$), purple areas (20.7% vs. 25.6%, $P: 0.459$), microulceration (9.8% vs. 4.9%, $P: 0.230$), and honeycomb appearance (8.5% vs. 3.7%, $P: 0.192$) (smokers and nonsmokers, respectively) [Figures 1-4]. All dermoscopic structures are shown in Table 1.

DISCUSSION

The properties of the capillary structures in the oral mucosa are probably a mirror of what happens in every organ of the human body.^[5] In the studies of microcirculation on retinal vessels, narrow retinal arteriole caliber has been

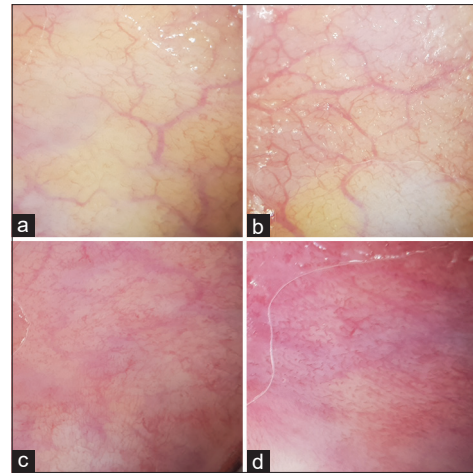


Figure 1: Clear reticular arrangement (a and b) and mixed reticular arrangement (c and d)

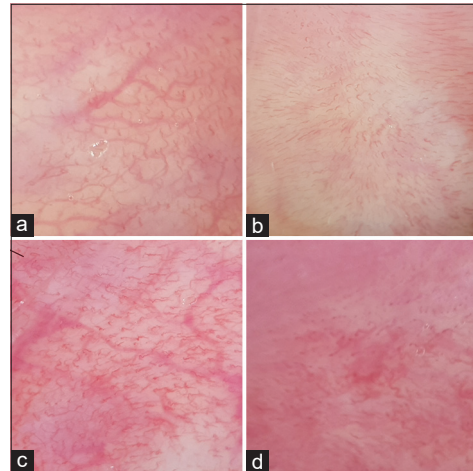


Figure 2: Chain-shaped hairpin vessels (a), grouped hairpin vessels (b), matchstick hairpin vessels (c and d)

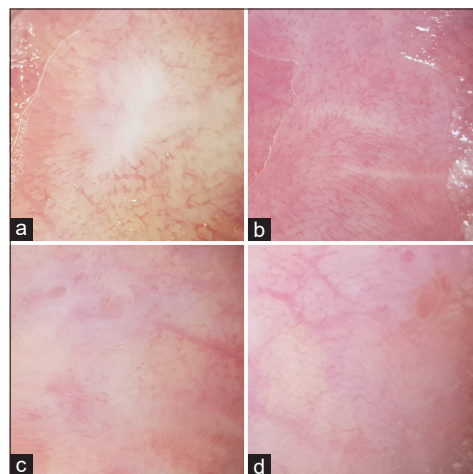


Figure 3: Yellowish-white streaks ([a] starburst-shaped, [b] linear), targetoid brown round areas ([c] in the upper left corner), microulceration ([d] in the upper right corner)

associated with hypertension and may even precede clinical hypertension.^[7,8] In contrast, larger retinal venular diameter

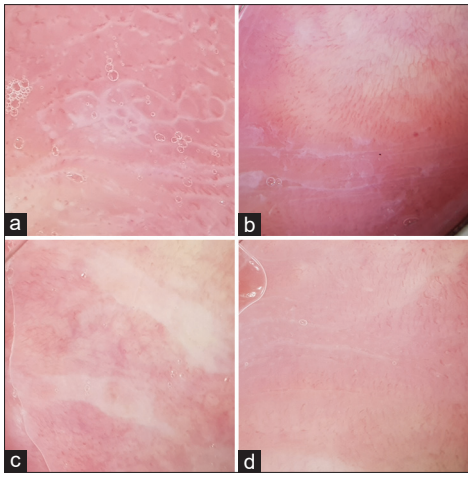


Figure 4: Honeycomb appearance (a), hyperkeratosis (a-d), white dot (a and d), grouped hairpin vessels (b and d), chain hairpin vessels, (a), hemorrhagic dot (b)

is associated with markers of systemic inflammation and various components of the metabolic syndrome (obesity, dyslipidemia, and hyperglycemia)^[9-11] and can also predict stroke and cardiovascular events.^[12-14] Smoking has both acute and chronic effects on microcirculation.^[6,15,16] It has been observed that smoking has negative effects on skeletal muscle, retinal, and coronary microcirculation.^[15-17] In the study evaluating the effects of smoking on the microcirculation of the oral labial mucosa by video capillaroscopy, smokers had lower diameter capillary loops, more visible capillary loops, lower background optical permeability, and more pronounced tortuous capillary loops.^[6] In our dermoscopic study, hemorrhagic dot, matchstick hairpin vessels, and microaneurysm were found to be significantly higher in smokers. Matchstick hairpin vessels have been defined as the condition where the loop portion of the hairpin vessels was more swollen, darker, and more pronounced than the branches.^[18] With this change, we think that hemorrhagic dot and microaneurysm may be caused by tortuous changes detected in capillaroscopic studies.

Other vascular structures such as deep vascular network, superficial vascular network, mixed reticular arrangement, clear reticular arrangement, chain hairpin vessels, grouped hairpin vessels, dot vessels, and glomerular vessels were not significantly different.

Information on the dermoscopy of the labial mucosa is limited, and in the literature, dermoscopic examination has been performed in several dermatological diseases of the labial mucosa.^[19-21] According to our previous dermoscopic experience of labial mucosa, we observed that hairpin vessels occur both in the normal labial mucosa and in the vicinity of any lesion localized to this region. In our study on oral mucocele dermoscopy, we detected hairpin vessels in 57.1% of the lesions.^[21] However, these vessels were rather large, prominent, and focusable than the chain and grouped hairpin vessels in the lesion-free labial mucosa.^[21]

Table 1: Dermoscopic features of smoker and nonsmoker group

Dermoscopic structures	Smoker group, n (%)	Nonsmoker group, n (%)	P
Deep vascular network	76 (92.7)	79 (96.3)	0.304
Superficial vascular network	74 (90.2)	79 (96.3)	0.119
Mixed reticular arrangement	68 (82.9)	61 (74.4)	0.182
Clear reticular arrangement	13 (15.9)	22 (26.8)	0.086
Grouped hairpin vessels	58 (70.7)	51 (62.2)	0.247
Dot vessels	45 (54.9)	39 (47.6)	0.349
Chain hairpin vessels	20 (24.4)	14 (17.1)	0.248
Microaneurysm	29 (35.4)	15 (18.3)	0.014
Matchstick hairpin vessels	31 (37.8)	13 (15.9)	0.002
Glomerular vessels	2 (2.4)	5 (6.1)	0.246
Yellow background areas	78 (95.1)	75 (91.5)	0.349
Purple areas	17 (20.7)	21 (25.6)	0.459
Hemorrhagic dot	40 (48.8)	22 (26.8)	0.004
Targetoid brown round areas	31 (37.8)	16 (19.5)	0.010
Yellowish-white streaks	25 (30.5)	22 (26.8)	0.604
Hyperkeratosis	31 (37.8)	15 (18.3)	0.005
White dot	18 (22)	8 (9.8)	0.033
Honeycomb appearance	7 (8.5)	3 (3.7)	0.192
Microulceration	8 (9.8)	4 (4.9)	0.230

In this study, targetoid brown round areas were significantly higher in smokers (37.8% vs. 19.5%, P : 0.010) than nonsmokers. While the center of these dermoscopic structures was brown, there was a white ring surrounding it. We think that these structures are improving microulceration.^[18] However, there was no significant difference between the two groups in terms of newly developed microulcerations. We think that the white dots and honeycomb appearance found in our study are different variants of hyperkeratosis. However, it was significant that hyperkeratosis and white dots were higher among smokers. Hyperkeratotic structures were sometimes linear.

There was no significant difference between the groups in terms of yellowish white streaks (30.5% vs. 26.8%, P : 604). We conclude that these structures are cicatricial structures secondary to trauma. These structures, which are generally linear, can be multiple and rarely in starburst pattern.

CONCLUSION

In this study, the effect of smoking on vascular and nonvascular structures such as microcirculation of labial mucosa was evaluated dermoscopically. In this study, we think that structures such as hemorrhagic dot, matchstick hairpin vessels, and microaneurysm, which are significantly higher in smokers, may be caused by microcirculation disorders. In addition, we believe that the possibility of smoking to make similar changes in other tissue and organ microcirculation should be considered in patients with these structures.

Financial support and sponsorship

Nil.

Conflicts of interest

There are no conflicts of interest.

REFERENCES

- Böttcher M, Falk E. Pathology of the coronary arteries in smokers and non-smokers. *J Cardiovasc Risk* 1999;6:299-302.
- Lehr HA. Microcirculatory dysfunction induced by cigarette smoking. *Microcirculation* 2000;7:367-84.
- Anderson TJ. Assessment and treatment of endothelial dysfunction in humans. *J Am Coll Cardiol* 1999;34:631-8.
- Barua RS, Ambrose JA, Srivastava S, DeVoe MC, Eales-Reynolds LJ. Reactive oxygen species are involved in smoking-induced dysfunction of nitric oxide biosynthesis and upregulation of endothelial nitric oxide synthase: An *in vitro* demonstration in human coronary artery endothelial cells. *Circulation* 2003;107:2342-7.
- Scardina GA, Cacioppo A, Messina P. Anatomical evaluation of oral microcirculation: Capillary characteristics associated with sex or age group. *Ann Anat* 2009;191:371-8.
- Lova RM, Miniati B, Macchi C, Gulisano M, Gheri G, Catini C, *et al.* Morphologic changes in the microcirculation induced by chronic smoking habit: A videocapillaroscopic study on the human labial mucosa. *Am Heart J* 2002;143:658.
- Wong TY, Klein R, Sharrett AR, Duncan BB, Couper DJ, Klein BE, *et al.* Retinal arteriolar diameter and risk for hypertension. *Ann Intern Med* 2004;140:248-55.
- Smith W, Wang JJ, Wong TY, Rochtchina E, Klein R, Leeder SR, *et al.* Retinal arteriolar narrowing is associated with 5-year incident severe hypertension: The Blue Mountains Eye Study. *Hypertension* 2004;44:442-7.
- Ikram MK, de Jong FJ, Vingerling JR, Witteman JC, Hofman A, Breteler MM, *et al.* Are retinal arteriolar or venular diameters associated with markers for cardiovascular disorders? The Rotterdam Study. *Invest Ophthalmol Vis Sci* 2004;45:2129-34.
- Klein R, Klein BE, Knudtson MD, Wong TY, Tsai MY. Are inflammatory factors related to retinal vessel caliber? The Beaver Dam Eye Study. *Arch Ophthalmol* 2006;124:87-94.
- Wong TY, Duncan BB, Golden SH, Klein R, Couper DJ, Klein BE, *et al.* Associations between the metabolic syndrome and retinal microvascular signs: The Atherosclerosis Risk In Communities study. *Invest Ophthalmol Vis Sci* 2004;45:2949-54.
- Ikram MK, de Jong FJ, Bos MJ, Vingerling JR, Hofman A, Koudstaal PJ, *et al.* Retinal vessel diameters and risk of stroke: The Rotterdam Study. *Neurology* 2006;66:1339-43.
- Wang JJ, Liew G, Wong TY, Smith W, Klein R, Leeder SR, *et al.* Retinal vascular calibre and the risk of coronary heart disease-related death. *Heart* 2006;92:1583-7.
- Wong TY, Kamineni A, Klein R, Sharrett AR, Klein BE, Siscovick DS, *et al.* Quantitative retinal venular caliber and risk of cardiovascular disease in older persons: The cardiovascular health study. *Arch Intern Med* 2006;166:2388-94.
- Kifley A, Liew G, Wang JJ, Kaushik S, Smith W, Wong TY, *et al.* Long-term effects of smoking on retinal microvascular caliber. *Am J Epidemiol* 2007;166:1288-97.
- Siafaka A, Angelopoulos E, Kritikos K, Poriazi M, Basios N, Gerovasili V, *et al.* Acute effects of smoking on skeletal muscle microcirculation monitored by near-infrared spectroscopy. *Chest* 2007;131:1479-85.
- Miyazaki T, Ashikaga T, Ohigashi H, Komura M, Kobayashi K, Isobe M. Impact of smoking on coronary microcirculatory resistance in patients with coronary artery disease. *Int Heart J* 2015;56:29-36.
- Ayhan E, Öztürk M, An I, Araç E. Dermoscopy of oral labial mucosa according to age and sex in healthy adults: First observational dermoscopic study. *Turk J Dermatol* 2019;13:135-9.
- Salah E. Clinical and dermoscopic spectrum of discoid lupus erythematosus: Novel observations from lips and oral mucosa. *Int J Dermatol* 2018;57:830-6.
- Kaminska-Winciorek G, Calik J, Wydmanowski J, Schwartz RA, Czajkowski R. Primary melanoma in rare locations: Clinical and dermoscopic features. *Indian J Dermatol Venereol Leprol* 2014;80:369-71.
- Ayhan E, Toprak SF, Kaya Ş, Akkaynak Ş. Dermoscopy of oral mucocele: Three type of extravasation mucocele. *Turk J Med Sci* 2019. doi: 10.3906/sag-1907-56. [Epub ahead of print].