

A Case of Generalized Granuloma Annulare with Diabetes Mellitus: Regressed with Antidiabetic Therapy

Sir,

Granuloma annulare (GA) is a benign necrobiotic granulomatous dermatosis of unknown cause, presenting as localized, generalized, perforating or subcutaneous lesions.^[1,2]

Diabetes has been reported to occur in up to 20% cases of GA.^[3] We present a case with diabetes mellitus (DM) that was diagnosed while the patient was being investigated for generalized GA (GGA), and his lesions improved after institution of treatment for DM.

A 65-year-old male presented with multiple itchy skin-colored raised lesions on the trunk and extremities of 1-month duration. There was no prior history of drug intake or insect bite hypersensitivity.

Cutaneous examination revealed multiple, well-defined, skin-colored to slightly erythematous papules and nodules on the extremity [Figure 1a], back [Figure 1b], and abdomen. Few of the lesions showed central umbilication and crusting. General and systemic examinations were within normal limit.

We considered differential diagnoses such as perforating dermatoses, prurigo nodularis, and GA. The patient was asked to get investigations, especially blood glucose, done.

The fasting blood sugar was 250.15 mg/dl and postprandial blood sugar was 409.19 mg/dl. Biopsy showed palisading granuloma with central collagen degeneration [Figure 1c]. An Alcian blue stain showed mucin at the center of granuloma [Figure 1d]. Hence, we diagnosed the case as a GA.

The patient was given oral metformin 500 mg twice daily with glimepiride 2 mg once daily and antihistaminic.

After 3 weeks of his follow-up, we noticed that his blood sugar level became apparently normal and surprisingly, almost all GGA lesions also subsided, leaving behind postinflammatory hyper-pigmentation [Figure 1e and f]. There was no recurrence at 9 months of follow-up.

GA was described by Calcott Fox in 1895 and named by Radcliffe Crocker in 1902. It is a benign, inflammatory disorder of unknown etiology.^[2]

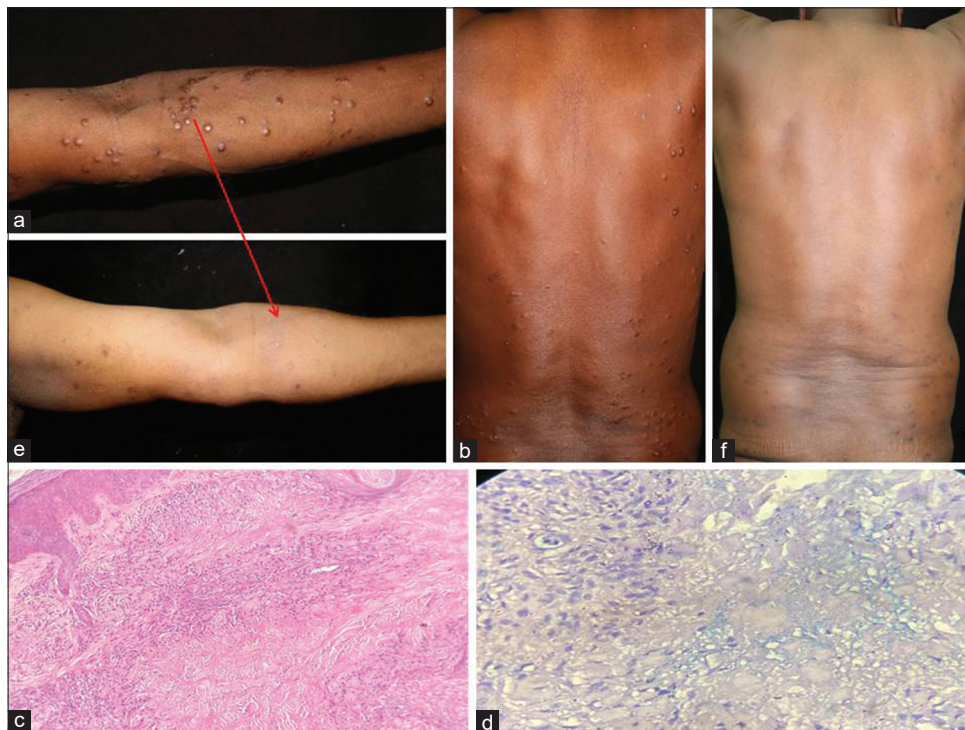


Figure 1: (a) Multiple, skin-colored, shiny papules with smooth surface on the inner aspect of the left upper extremity. (b) Multiple, skin-colored to hyperpigmented papules with central umbilication and crusting on the back. (c) Palisading granuloma in the superficial and mid dermis around the focus of mucin deposition and necrobiosis (H and E, $\times 10$). (d) Mucin within the center of palisaded granuloma (Alcian blue, $\times 40$). (e and f) After 3 weeks of antidiabetic therapy, the papular lesions completely resolved with residual hyper-pigmentation

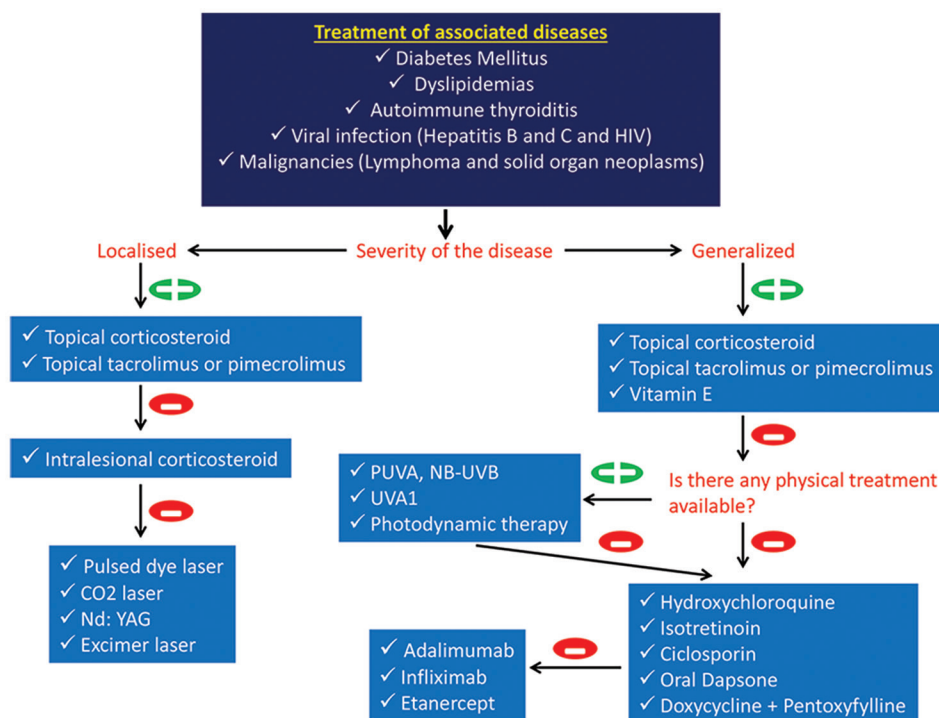


Figure 2: Treatment algorithm figure

How DM triggers GA is unknown. The increased serum glucose level or the resistance of insulin may change the structure of dermal blood vessels. Another possibility is that it can trigger the disease onset by damaging the structure of dermal collagen.

GGA in diabetes presents as a diffuse papular eruption, with pruritus being the prominent complaint. It differs from the localized form by a later age of onset, protracted course with only rare spontaneous resolution, poor response to therapy, and increased prevalence of human leukocyte antigen Bw 35.^[4]

Most cases of GA resolve spontaneously. Though natural resolution is a possible mechanism, biopsy as a triggering factor for resolution cannot be ruled out. Muzeyyen *et al.*^[5] noted that GGA lesions regressed after the regulation of serum glucose level with antidiabetic therapy and contributed to the information of relationship between GA and DM in the etiopathogenesis of GA.

Various methods are used in the treatment of GA [the treatment algorithm figure is depicted in Figure 2].

Although we cannot exclude the possibility of spontaneous regression of the lesions of GA in our patient, and the effect of biopsy-induced trauma on the disease course, we believe that the lesions regressed by instituting antidiabetic therapy, as the lesions were persisting and deteriorating for 1 month prior to the patient presenting to us.

Declaration of patient consent

The authors certify that they have obtained all appropriate patient consent forms. In the form the patient(s) has/have given his/her/their consent for his/her/their images and other

clinical information to be reported in the journal. The patients understand that their names and initials will not be published and due efforts will be made to conceal their identity, but anonymity cannot be guaranteed.

Financial support and sponsorship

Nil.

Conflicts of interest

There are no conflicts of interest.

Hari Pathave, Vaibhav Barve, Hanamant Gadade, Chitra Nayak

Department of Dermatology, BYL Nair Charitable Hospital and TNMC, Mumbai, Maharashtra, India

Address for correspondence: Dr. Hanamant Gadade, Department of Dermatology, BYL Nair Charitable Hospital and TNMC, Mumbai, Maharashtra, India.

E-mail: hanamantgadade03@gmail.com

REFERENCES

1. Cohen PR, Carlos CA. Granuloma annulare mimicking sarcoidosis: Report of patient with localized granuloma annulare whose skin lesions show 3 clinical morphologies and 2 histology patterns. *Am J Dermatopathol* 2015;37:547-50.
2. Burns DA. Necrobiotic disorders. In: Burns T, Breathnach S, Cox NH, Griffiths C, editors. *Rook's Text Book of Dermatology*. 8th ed. Oxford: Wiley-Blackwell; 2010. p. 60.1-12.
3. Garg S, Baveja S. Generalized granuloma annulare treated with monthly rifampicin, ofloxacin, and minocycline combination therapy. *Indian J Dermatol* 2013;58:197-9.
4. Friedman-Birnbaum R, Haim S, Gideone O, Barzilai A. Histocompatibility antigens in granuloma annulare. Comparative study of the generalized and localized types. *Br J Dermatol* 1978;98:425-8.
5. Muzeyyen G, Secil S, Oguzhan K, Ulker G, Murat D. A case of

generalized granuloma annulare that contributed to the diagnosis of diabetes mellitus and regressed with antidiabetic therapy. *Turkiye Klinikleri J Dermatol* 2009;19:23-6.

Submission: 02-05-2020

Revision: 05-05-2020

Acceptance: 09-06-2020

Web Publication: 17-09-2020

This is an open access journal, and articles are distributed under the terms of the Creative Commons Attribution-NonCommercial-ShareAlike 4.0 License, which allows others to remix, tweak, and build upon the work non-commercially, as long as appropriate credit is given and the new creations are licensed under the identical terms.

Access this article online

Quick Response Code:



Website:

www.tjdonline.org

DOI:

10.4103/TJD.TJD_43_20

How to cite this article: Pathave H, Barve V, Gadade H, Nayak C. A case of generalized granuloma annulare with diabetes mellitus: Regressed with antidiabetic therapy. *Turk J Dermatol* 2020;14:79-81.

© 2020 Turkish Journal of Dermatology | Published by Wolters Kluwer - Medknow